Received: 31 March 2023 | Accepted: 16 May 2023

DOI: 10.1111/dmcn.15676

INVITED REVIEW

Retinodural haemorrhage of infancy, abusive head trauma, shaken baby syndrome: The continuing quest for evidence

Waney Squier*

Department of Neuropathology, John Radcliffe Hospital, Oxford, UK

Correspondence
Waney Squier
Email: waney.squier@gmail.com

Abstract
The shaken baby syndrome was originally proposed in the 1970s without any formal scientific basis. Once data generated by scientific research was available, the hypothesis became controversial. There developed essentially two sides in the debate. One side claimed that the clinical triad of subdural haemorrhage, retinal haemorrhage, and encephalopathy, or its components, is evidence that an infant has been shaken. The other side stated this is not a scientifically valid proposal and that alternative causes, such as low falls and natural diseases, should be considered. The controversy continues, but the contours have shifted. During the last 15 years, research has shown that the triad is not sufficient to infer shaking or abuse and the shaking hypothesis does not meet the standards of evidence-based medicine. This raises the issue of whether it is fit for either clinical practice or for the courtroom; evidence presented to the courts must be unassailable.

In 2008 I wrote a short review 'Shaken Baby Syndrome: the quest for evidence'.[1] Here I update that review and point to changes in our understanding of the concept over the last 15 years.

In the 1970s doctors were anxious about the spectre of children being abused by their parents. Infants were seen in hospital with multiple fractures, bruising, subdural haemorrhage (SDH), and failure to thrive. But some infants had only intracranial and neurological findings, without any of the external and radiological signs of trauma. In order to explain this, the possibility that these infants had been shaken was proposed.[2] This led to the development of a hypothesis that the presence of the 'triad' of SDH, retinal haemorrhage, and encephalopathy was evidence of shaking. This hypothesis was readily accepted and incorporated into medical textbooks and teaching as the shaken baby syndrome (SBS), despite the fact that it had not been subjected to any scientific testing. The first clinical and biomechanical research over a decade later showed that shaking could not account for the triad unless accompanied by impact.[3] Further research has demonstrated the lack of scientific support for the hypothesis (Figure 1), yet it continues to be widely believed and used as the basis for criminal prosecutions and for removing infants from their families.

RENAMING: SHAKEN BABY SYNDROME BECOMES ABUSIVE HEAD TRAUMA

In 2009 the American Academy of Pediatrics advocated use of the term 'abusive head trauma' (AHT) as inclusive of all mechanisms of injury, including shaking.[4] The breadth of this new definition is confusing; there is no controversy about the existence of child abuse or that the triad of SDH, retinal haemorrhage, and encephalopathy may follow trauma and impact. The controversy is specifically about shaking, and whether any constellation of clinical and/or imaging findings can reliably distinguish between natural or accidental causes and deliberate shaking. The preferred term, retinodural haemorrhage of infancy,[5] describes the objective findings, makes no presuppositions, and avoids the implications of intent inherent in both SBS and AHT. Indeed, a doctor

Abbreviations: AHT, abusive head trauma; CVT, cortical vein thrombosis; SBS, shaken baby syndrome; SBU, Swedish Agency for Health Technology Assessment and Assessment of Social Services; SDH, subdural haemorrhage.

*No longer at this institution.

 © 2023 Mac Keith Press.

using these terms may overstep their role by making a legal determination rather than a diagnosis.

> Notwithstanding the propriety of a diagnosis of inflicted trauma, we conclude that in cases involving allegations of abuse, an expert goes too far when he or she diagnoses the injury as 'abusive head trauma' or opines that the inflicted trauma amounted to child abuse. The ordinary understanding of the term 'abuse'—as opposed to neglect or carelessness—implies a level of willfulness and moral culpability that implicates the defendant's intent or knowledge when performing the act that caused the head trauma. An expert may not offer an opinion on the intent or criminal responsibility of the accused.[6]

They may also be considered to breach medical professional ethics.[7]

What this paper adds

- There is insufficient scientific evidence to assume that an infant with the triad of subdural haemorrhage (SDH), retinal haemorrhage, and encephalopathy must have been shaken.
- Biomechanical and animal studies have failed to support the hypothesis that shaking can cause SDH and retinal haemorrhage.
- Patterns of retinal haemorrhage cannot distinguish abuse.
- Retinal haemorrhages are commonly associated with extracerebral fluid collections (including SDH) but not with shaking.
- Infants can develop SDH, retinal haemorrhage, and encephalopathy from natural diseases and falls as low as 1 foot.
- The shaking hypothesis and the literature on which it depends do not meet the standards of evidence-based medicine.

THE DEMISE OF THE TRIAD

Shortly after the name change, supporters of the shaking hypothesis began to disavow the triad of SDH, retinal haemorrhage, and encephalopathy which was fundamental to the original shaking hypothesis. They described it as a myth, a straw man, denying that the term ever had currency: '[t]he complex features of AHT are often disparagingly distilling [*sic*] simply to "The Triad"; a term devoid of any real clinical meaning and not used at all in practice'.[8] Despite this, one-third of cases in a small study of confessed or convicted abuse were based on the triad alone,[9] 'triad only' cases are still regularly decided in the British family courts, and a 2022 review concluded that the presence of the triad justifies concern for abuse.[10]

A MAJOR LITERATURE REVIEW

Shortly after several high profile shaken baby convictions were overturned in Sweden,[11] the Swedish Agency for Health Technology Assessment and Assessment of Social Service

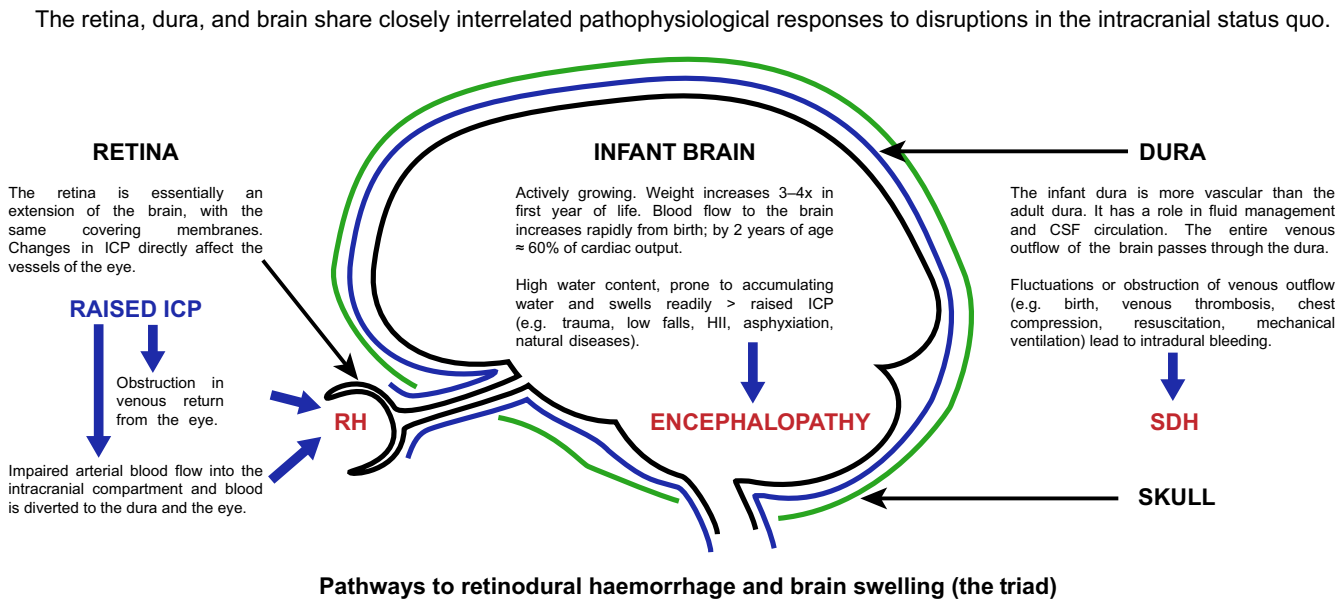

FIGURE 1 Pathways to retinodural haemorrhage and brain swelling (the triad). Abbreviations: CSF, cerebrospinal fluid; HII, hypoxic-ischaemic injury; ICP, intracranial pressure; RH, retinal haemorrhage; SDH, subdural haemorrhage.

14698749, 0, Downloaded from https://onlinelibrary.wiley.com/doi/10.1111/dmcn.15676 by University College London UCL Library Services, Wiley Online Library on [24/06/2023]. See the Terms and Conditions (https://onlinelibrary.wiley.com/terms-and-conditions) on Wiley Online Library for rules of use; OA articles are governed by the applicable Creative Commons License

(SBU; similar to the National Institute for Health and Care Excellence in the UK) published an independent review. Reviewing over 3700 published papers,[7] the study found only very low quality evidence to support the shaking hypothesis, represented by just two papers, each based on confession evidence and each categorized as having a moderate risk of bias. The majority of the SBS literature suffered from fundamental methodological problems, particularly circular reasoning and lack of control groups. The authors concluded that there is insufficient scientific evidence to assume that an infant with the triad, or any of its components, must have been shaken. The paper was met with critical responses and even calls for it to be withdrawn. The authors provided comprehensive and robust rebuttals.[12–14]

THE REJOINDER: A CONSENSUS STATEMENT

In response to the SBU report, supporters of the SBS/AHT hypothesis issued a 'consensus' statement.[15] It did not provide new evidence but instead was aimed at establishing 'general acceptance', which would add weight to expert evidence for the courts.

The statement included subdural hematoma, intracranial and spinal changes, complex retinal haemorrhages, rib and other fractures among the components said to be characteristic of AHT. Shaking with or without impact was considered the mechanism of injury, based on the medical literature, 'overwhelming clinical experience and judgment' and confessions.

The statement advocates that in every case the question is asked: 'Is there a medical cause to explain the findings or did this child suffer from inflicted injury?'

Support for the statement

The statement draws support from a questionnaire sent to physicians involved in the evaluation of injured children at 10 hospitals in the USA.[16] Only 40% of pathologists surveyed considered SBS to be a valid diagnosis but, as expected, acceptance of AHT was high (93%). The claim that there is no medical controversy concerning this diagnosis results from conflating AHT with SBS. No one doubts that AHT exists; the specific point at issue is whether certain intracranial findings can indicate a mechanism of shaking and, by implication, abuse.

The statement also relies on a series of meta-analyses from Cardiff University claiming that certain combinations of clinical features yield a high probability of abuse.[17] These meta-analyses depend on studies flawed by circularity and the inability to accurately determine abuse. There is no standard criterion to recognize abuse. In most cases the diagnosis is 'probabilistic' depending on multidisciplinary assessment. This is itself a clinical best guess based on the presence of the very findings which are under study. So all infants with the triad (or triad with/without other selected criteria) will be categorized as abused and the results will show that all infants with a diagnosis of abuse will have the triad (with/without other criteria). So the positive predictive value of the test becomes absolute: 100%. This may impress legal factfinders, but to scientists it rings alarm bells. This result is too good to be true, reflecting the circularity of the adopted methodology. The authors have acknowledged that 'a (rounded) probability score of 100% gives an uncomfortable level of diagnostic certainty'.[18] These meta-analyses do not determine the accuracy of the diagnostic methods; they simply predict the likelihood that specific findings will be categorized as abusive and, consequently, the likelihood that carers will be accused of abuse.

The Cardiff meta-analyses were assessed by the SBU as of low quality because of a high risk of bias[7] and their methodology has been further challenged.[19] Yet these studies continue to have critical importance in informing medical evidence in the courts, and, despite their flaws, have been adopted in their entirety as the evidence base for the Child Protection Guidelines of the Royal College of Paediatrics and Child Health.

Evidence undermining the statement

The consensus statement is undermined by the lack of objective, scientifically validated evidence to support its claims. The authors did not address the flaws in the literature on which it relies. The dependence on clinical experience and affirmation by professional bodies is not science, and confessions are unreliable.

The statement did not follow the scientific principles to formally establish medical consensus; the process described was of review between societies' governing bodies and their own appointed committees without reference to external audit. One of the authors subsequently wrote: 'Albeit low on the hierarchy of evidence-based medicine ratings, professional society consensus statements represent the highest level of medico-legal evidence',[20] implicitly admitting that the consensus statement does not meet the standards of evidence-based medicine, yet is good enough for the courts.

Confessions

Confessions are known to be unreliable; DNA evidence shows that false confessions to serious crimes occur in approximately 25% of exonerations.[21] The two research studies found by the SBU to support the shaking hypothesis were confession studies from France.[22, 23] In both studies, confessions were obtained during judicial proceedings, after a diagnosis of abuse had been made. During police interrogation, the diagnosis of shaking may be presented as certain and irrefutable and, although there is no formal plea-bargaining system in France, confession may be coerced by offers of leniency or return of the infant.[24] Given the significance of confessions in the shaken baby hypothesis, their quality is

14698749, 0, Downloaded from https://onlinelibrary.wiley.com/doi/10.1111/dmcn.15676 by University College London UCL Library Services, Wiley Online Library on [24/06/2023]. See the Terms and Conditions (https://onlinelibrary.wiley.com/terms-and-conditions) on Wiley Online Library for rules of use; OA articles are governed by the applicable Creative Commons License

critical. It would be improved if only spontaneous and uncoerced confessions were used.[25]

Biomechanics

Biomechanical studies have always been a problem for the shaking hypothesis. In 2015 Jones et al. wrote: 'no study has to date demonstrated that shaking alone, without an associated impact, exceeds the injury thresholds associated with SDH.'[26]

Animal models have similarly failed to support the shaking hypothesis. Finnie and Blumbergs concluded in 2022 that no animal model has been able to reliably reproduce the full range of neuropathological changes attributed to AHT.[27]

CURRENT EVIDENCE AND THE TRIAD

Retinal haemorrhages

Infant retinal haemorrhages have many causes. They are associated with cerebral oedema and SDH, which was found in 97.6% of infants with retinal haemorrhages.[28] These studies confirm traditional teaching that retinal haemorrhages are 'pathognomonic' of SDH.[29] Thiblin et al. found that all infants with bilateral retinal haemorrhage had intracranial pathology, usually extracerebral fluid collections; conversely only 2 of 27 infants, witnessed or spontaneously admitted to have been shaken, had retinal haemorrhages.[30]

Raised intracranial pressure is associated with retinal haemorrhage in children, independent of age and aetiology.[31] Mattheij et al. wrote: 'Clinicians should also know that there is no pathognomonic size, distribution, or location of [retinal hemorrhages] seen only in AHT.'[32]

Over the years, the diagnostic value of retinal haemorrhage for AHT evolved from simply being present to depending on specific patterns such as dense, extensive, and extending to the ora serrata. However in 2020, Binenbaum, an ophthalmologist and protagonist of the shaken baby hypothesis, effectively refuted previous claims for the specificity of retinal haemorrhage for shaking, saying that patterns that might distinguish traumatic from medical causes of retinal haemorrhage are not perfectly correlated with abuse: 'there is generally more overlap than appreciated between abusive and accidental retinal hemorrhages.'[33]

Subdural haemorrhage

Patterns of SDH thought to determine abuse have also changed. From merely being present, now bilateral, interhemispheric, or multi-compartment SDH are assumed to have specific diagnostic significance. Among infants suspected to have been abused, over 80% have chronic SDH and there is an association with male sex and preterm birth.[34]

The shaking hypothesis posits that SDH is from ruptured bridging veins. While ruptured bridging veins may cause SDH, other sources are now acknowledged, notably the thin-walled vessels in healing subdural membranes as well as the dura itself. It is therefore unsafe to conclude that the presence of SDH indicates that bridging veins are ruptured and that significant trauma has occurred.

Encephalopathy

Recent studies have highlighted the association and severity of encephalopathy in AHT. Hymel et al.[10] compared patients with witnessed or confessed AHT versus witnessed non-AHT. The combination of 'the triad' and 'the absence of signs of impact' was perfectly specific and predictive for AHT. But the study groups were not comparable; patients with AHT more frequently had evidence of brain hypoxia, ischaemia, swelling, prolonged encephalopathy, and seizures. Similarly Bhardwaj et al.,[35] comparing infants with abusive and accidental head injuries, found retinal haemorrhages were positively associated with head injury severity, but the 'abuse' group had more severe head injuries. Neither study controlled for the degree of cerebral injury. The data in these studies can be interpreted as showing that the triad and/or retinal pathology are markers of the degree of intracranial pathology and hypoxic-ischaemic injury, rather than of shaking. Both studies are flawed by circular logic.

Studying spinal injuries, Rabbitt et al.[36] found that a range of findings seen on magnetic resonance imaging (MRI) (ligament injury, posterior paraspinous muscle oedema, prevertebral soft-tissue swelling, intramedullary haemorrhage, spinal epidural haemorrhage, vertebral body compression fractures with bone marrow oedema, and vertebral artery dissection) were not associated with AHT, but with more severe brain injury. Choudhary et al.[37] described a correlation between occipito-cervical ligamentous changes and cerebral hypoxic-ischaemic injury.

These studies appear to justify the controversial Geddes hypothesis that the triad resulted from abnormal intracranial haemodynamics and hypoxia, which was the chief challenge to SBS in 2008.[38] They certainly confirm the association between cerebral hypoxic-ischaemic injury and the triad.

Neck injuries

One of the major difficulties with the hypothesis was that shaking of sufficient force to cause intracranial injury would surely damage the infant neck. Infants who suffer whiplash in forward facing car seats generally have fractures and dislocations of the cervical spine, not the triad. Biomechanical simulation of this scenario showed cervical spine injury is 30 times more likely than head injury in whiplash.[39]

14698749, 0, Downloaded from https://onlinelibrary.wiley.com/doi/10.1111/dmcn.15676 by University College London UCL Library Services, Wiley Online Library on [24/06/2023]. See the Terms and Conditions (https://onlinelibrary.wiley.com/terms-and-conditions) on Wiley Online Library for rules of use; OA articles are governed by the applicable Creative Commons License

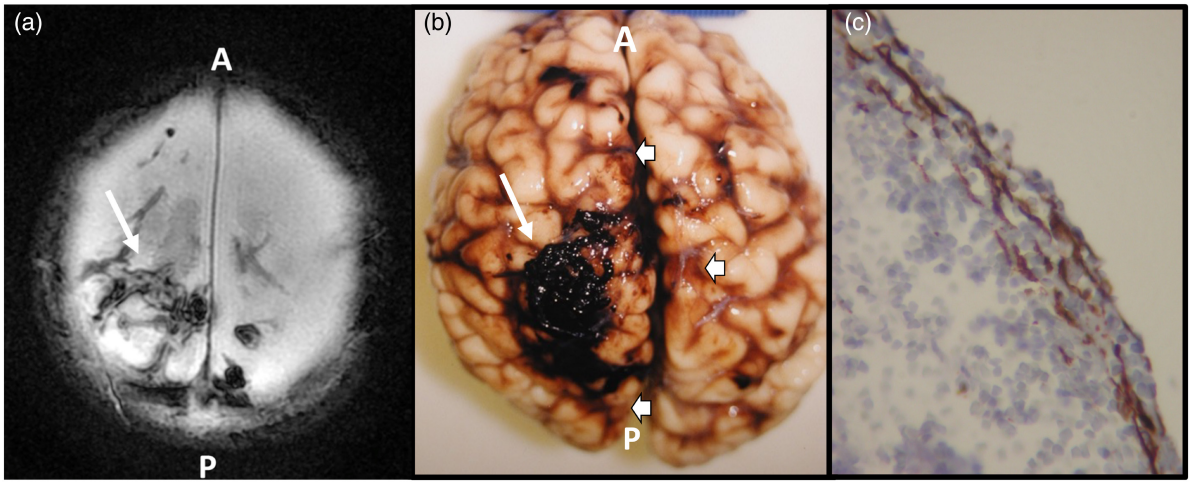

FIGURE 2 Venous thrombosis and diapedesis: lollipops and tadpoles. (a) Magnetic resonance imaging scan. Areas of clot/thrombosis 'bloom' on T2* (white arrow) and are closely aligned with cortical and bridging veins. (b) Fresh brain (different case) showing congested varicose and thrombosed veins (white arrow) with small amounts of adjacent subarachnoid blood (block arrows). (c) Diapedesis. Vein wall stained with smooth muscle actin showing red cells (stained blue) migrating between the cells in the wall of a thrombosed vein. Abbreviations: A, anterior midline; P, posterior midline.

Spinal MRI findings are increasingly used as adjunctive evidence of abuse, particularly spinal subdural bleeding and paraspinal injury. It is well established that blood in the spinal subdural compartment tracks down from the cranial compartment and settles in the dorsal thoracolumbar area. A study of infants with spinal SDH showed them all to have coexisting posterior fossa SDH of similar MRI intensity; those with thoracolumbar SDH had no bony or ligamentous injuries at this level.[37]

Paraspinal soft-tissue changes, identified on MRI as 'ligamentous injury' and paraspinous muscle and soft-tissue oedema, have also been associated with AHT.[37] Yet MRI spine has at best moderate specificity for paraspinous muscle injury when compared with intraoperative observations.[40] In the absence of autopsy confirmation that this represents genuine traumatic damage, the finding needs to be interpreted with caution.

ALTERNATIVE EXPLANATIONS FOR THE TRIAD

Low falls

In 2008 it was thought that low falls could not cause the triad but biomechanical evidence demonstrated that low falls produce far greater head acceleration than shaking. In 2018 eight infants were described who developed SDH and retinal haemorrhages after low level falls onto the occiput.[41] Hughes et al.[42] described infants with skull fracture or intracranial injury after falls from standing or sitting with a mean height of 0.66m (+/- 0.29m) (i.e. some were injured after falls from only about 1 foot).

Cortical vein thrombosis

Proponents of SBS repeatedly state that cortical vein thrombosis (CVT) does not cause SDH[15, 43] and so cannot be a cause of the triad. However SDH is described in patients with CVT, for example SDH was seen in 20% of infants with CVT.[43] In some cases SDH preceded CVT, which is not surprising as SDH promotes an inflammatory response which is a common mechanism for both CVT and SDH.

Thrombosed bridging veins, tadpoles, and lollipops

Radiological identification of rounded or linear images of bridging veins, labelled 'lollipop' or 'tadpole' signs, is said to indicate ruptured bridging veins which, in the presence of multifocal SDH, allow a 'certain' diagnosis of AHT.[44] Objections to this hypothesis are multiple. Traumatic tearing of a bridging vein will result in immediate bleeding, followed some time later by clotting. A ruptured vessel would be surrounded by a significant volume of blood which obscures it at autopsy[45] and on scans. Therefore, structures on imaging described as 'lollipops' and 'tadpoles' are very unlikely to represent ruptured veins. They can only be visualized because they are surrounded by fluid, not by extravasated blood. Most importantly, pathological confirmation that these are ruptured veins is completely lacking. Red blood cells escape from stretched, thrombosed vein walls (diapedesis). This small amount of perivenous leakage would explain lollipops and tadpoles (Figure 2). It does not depend on traumatic tearing but occurs in thrombosis of any cause. There is no evidence that imaging findings

14698749, 0, Downloaded from https://onlinelibrary.wiley.com/doi/10.1111/dmcn.15676 by University College London UCL Library Services, Wiley Online Library on [24/06/2023]. See the Terms and Conditions (https://onlinelibrary.wiley.com/terms-and-conditions) on Wiley Online Library for rules of use; OA articles are governed by the applicable Creative Commons License

of thrombosed bridging veins correlate with bridging vein rupture.[46]

Extracerebral fluid collections

Benign enlargement of the subarachnoid space, or benign or idiopathic external hydrocephalus, predominantly affects male infants whose head circumference increases rapidly during the first months of life. The clinical presentation includes seizures, vomiting and retinal haemorrhages, subdural collections, or chronic SDH, all features common to SBS, for which benign enlargement of the subarachnoid space is sometimes misdiagnosed.[47] The determination of SBS in infants with benign enlargement of the subarachnoid space cannot be confirmed without corroborating evidence of trauma.[48]

RANCOUR

One of the most regrettable developments in the last 15 years is increasing rancour in this debate. Those of us who specifically challenge the shaking mechanism are labelled as 'denialists'. Statements such as 'denialism of child abuse has become a significant medical, legal and public health problem'[15] are misleading. We do not deny the existence of child abuse but deny that the triad, or any one of its elements (SDH, retinal haemorrhages, or encephalopathy), can alone be used as a diagnostic marker for shaking.

Inappropriate name-calling is not the only kind of rancour. There have been calls to censure those who disagree with the original hypothesis,[49] as well as calls to retract the SBU report. An academic journal foundered because of pressure placed on a publisher wishing to publish a debate by proponents and challengers of SBS.[50] Experts challenging the orthodoxy have been charged with perjury, subjected to complaints to medical boards and to the General Medical Council.[51] The tenor of the debate is reflected in an academic review of a paper challenging the hypothesis saying 'X's study can be discounted. He's a lousy and dishonest researcher'[52] and an invited review of a proposal for a textbook on SBS stated 'because I am of an opinion opposite to the authors' I consider it dangerous to publish such contents, which can do a lot of harm'. Despite this review, the book has just been published.[53]

CONCLUSION

The necessity to clearly identify real child abuse remains as urgent as ever so that children can be protected from further abuse and grow up in safety. Research over the last 15 years has shown that the presence of the triad of SDH, retinal haemorrhage, and encephalopathy is not sufficient to infer that shaking or abuse have occurred. The association of all three elements of the triad with both medical conditions and accidents has been repeatedly demonstrated. The problems of circularity and inadequate control groups pervade the literature relied upon to justify the diagnosis of AHT. The courts must be made aware of these problems. Better research is needed. Epidemiological studies from Scandinavia, drawing on databases virtually unparalleled elsewhere have already borne fruit;[25, 30] more are needed.

Sadly the degree of animosity between those on either side of the debate has risen to such a level that doctors are afraid to give evidence challenging the SBS hypothesis for fear of criticism or, worse, losing their licence. This leaves families exposed; the wrongfully accused are unable to find medical experts to support a justified defence. Guthkelch stated in 2012: 'while controversy is a normal and necessary part of scientific discourse, there has arisen a level of emotion and divisiveness on shaken baby syndrome/abusive head trauma that has interfered with our commitment to pursue the truth.'[5] It is to that part of the equation that we now must turn; that the progress in scientific understanding can be put into evidence in the courts, and that experts are not afraid to do so.

DATA AVAILABILITY STATEMENT

Data sharing not applicable to this article as no datasets were generated or analysed during the current study.

ORCID

Waney Squier https://orcid.org/0000-0003-4183-3343

REFERENCES

1. Squier W. Shaken baby syndrome: the quest for evidence. Dev Med Child Neurol. 2008 Jan;50(1):10–4.
2. Guthkelch AN. Infantile Subdural Haematoma and its Relationship to Whiplash Injuries. BMJ. 1971 May 22;2(5759):430–1.
3. Duhaime AC, Gennarelli TA, Thibault LE, Bruce DA, Margulies SS, Wiser R. The shaken baby syndrome: A clinical, pathological, and biomechanical study. J Neurosurg. 1987 Mar;66(3):409–15.
4. Christian CW, Block R. Abusive Head Trauma in Infants and Children. Pediatrics. 2009 May 1;123(5):1409–11.
5. Guthkelch AN. Problems of infant retino-dural hemorrhage with minimal external injury. Houst J Health Law Policy. 2012;ISSN:1534–7907:201–8.
6. State of Michigan v McFarlane. Allegan Circuit Court; 2018. LC No. 14-018862-FC.
7. Elinder G, Eriksson A, Hallberg B, et al. Traumatic shaking. The role of the triad in medical investigations of suspected traumatic shaking – a systematic review. Stockholm: Swedish Agency for Health Technology Assessment and Assessment of Social Services (SBU; 2016. Report No.: 255E/2016.
8. Greeley CS. 'Shaken baby syndrome' and forensic pathology. Forensic Sci Med Pathol. 2014 Jun;10(2):253–5.
9. Lynøe N, Eriksson A. Is focusing on the triad in suspected child abuse cases really irrelevant and of no practical use? Acta Paediatr. 2018 Oct;107(10):1675–6.
10. Hymel KP, Boos SC, Armijo-Garcia V, Musick M, Weeks K, Haney SB, et al. An analysis of physicians' diagnostic reasoning regarding pediatric abusive head trauma. Child Abuse Negl. 2022 Jul;129:105666.
11. Swedish Supreme Court MM. Swedish Supreme Court Stockholm; 2014. B 4560-11.

14698749, 0, Downloaded from https://onlinelibrary.wiley.com/doi/10.1111/dmcn.15676 by University College London UCL Library Services, Wiley Online Library on [24/06/2023]. See the Terms and Conditions (https://onlinelibrary.wiley.com/terms-and-conditions) on Wiley Online Library for rules of use; OA articles are governed by the applicable Creative Commons License

12. Lynøe N, Elinder G, Hallberg B, Rosén M, Sundgren P, Eriksson A. Is accepting circular reasoning in shaken baby studies bad science or misconduct? Acta Paediatr. 2017 Sep;106(9):1445–6.
13. Lynøe N, Eriksson A. No similarities between the Wakefield report on measles, mumps and rubella vaccine and the Swedish report on traumatic shaking. Acta Paediatr. 2020 Jul;109(7):1326–9.
14. Rosén M, Lynøe N, Elinder G, Hallberg B, Sundgren P, Eriksson A. Shaken baby syndrome and the risk of losing scientific scrutiny. Acta Paediatr. 2017 Dec;106(12):1905–8.
15. Choudhary AK, Servaes S, Slovis TL, Palusci VJ, Hedlund GL, Narang SK, et al. Consensus statement on abusive head trauma in infants and young children. Pediatr Radiol. 2018 Aug;48(8):1048–65.
16. Narang SK, Estrada C, Greenberg S, Lindberg D. Acceptance of Shaken Baby Syndrome and Abusive Head Trauma as Medical Diagnoses. J Pediatr. 2016 Oct;177:273–8.
17. Maguire SA, Kemp AM, Lumb RC, Farewell DM. Estimating the Probability of Abusive Head Trauma: A Pooled Analysis. Pediatrics. 2011 Sep 1;128(3):e550–64.
18. Cowley LE, Maguire SA, Farewell DM, Kemp AM. Letter to Editor. Law Probab Risk. 2018 Sep 1;17(3):275–7.
19. Cuellar M. Causal reasoning and data analysis: problems with the abusive head trauma diagnosis. Law Probab Risk. 2017 Dec 1;16(4):223–39.
20. Narang S. Combating misinformation about abusive head trauma: AAP endorses new report. AAP News. June 1st 2018.
21. Barnes P, Findley K, Moran D, Squier W. Shaken Baby Syndrome, Abusive Head Trauma, and Actual Innocence: Getting it Right. Houst J Health Policy. 2012;12:209–312.
22. Adamsbaum C, Grabar S, Mejean N, Rey-Salmon C. Abusive Head Trauma: Judicial Admissions Highlight Violent and Repetitive Shaking. PEDIATRICS. 2010 Sep 1;126(3):546–55.
23. Vinchon M, de Foort-Dhellemmes S, Desurmont M, Delestret I. Confessed abuse versus witnessed accidents in infants: comparison of clinical, radiological, and ophthalmological data in corroborated cases. Childs Nerv Syst. 2010 May;26(5):637–45.
24. Rossant C, Brook C. Why admitted cases of AHT make a low quality reference standard: A survey of people accused of AHT in France. Forensic Sci Int Synergy. 2023;6:100312.
25. Thiblin I, Andersson J, Wester K, Högberg G, Högberg U. How do we know that infant abusive head trauma has occurred? Acta Paediatr. 2022 Apr;111(4):888–9.
26. Jones MD, Martin PS, Williams JM, Kemp AM, Theobald P. Development of a computational biomechanical infant model for the investigation of infant head injury by shaking. Med Sci Law. 2015 Oct;55(4):291–9.
27. Finnie JW, Blumbergs PC. Animal models of pediatric abusive head trauma. Childs Nerv Syst. 2022 Dec;38(12):2317–24.
28. Kato M, Nonaka M, Akutsu N, Narisawa A, Harada A, Park YS. Correlations of intracranial pathology and cause of head injury with retinal hemorrhage in infants and toddlers: A multicenter, retrospective study by the J-HITs (Japanese Head injury of Infants and Toddlers study) group. Bayoumi NHL, editor. PLOS ONE. 2023 Mar 17;18(3):e0283297.
29. Till K. Subdural Haematoma and Effusion in Infancy. BMJ. 1968 Aug;3(5615):400–2.
30. Thiblin I, Andersson J, Wester K, Högberg G, Högberg U. Retinal haemorrhage in infants investigated for suspected maltreatment is strongly correlated with intracranial pathology. Acta Paediatr. 2021 Oct 28;apa.16139.
31. Minns RA, Jones PA, Tandon A, Fleck BW, Mulvihill AO, Minns FC. Raised intracranial pressure and retinal haemorrhages in childhood encephalopathies. Dev Med Child Neurol. 2017 Jun;59(6):597–604.
32. Mattheij M, Venstermans C, de Veuster I, Vanderstraete I, Menovsky T, Jorens P, et al. Retinal haemorrhages in a university hospital: not always abusive head injury. Acta Neurol Belg. 2017 Jun;117(2):515–22.
33. Binenbaum G. Recognizing retinal hemorrhage patterns aids in diagnosing abuse [Internet]. Available from: https://www.healio.com/news/ophthalmology/20210413/recognizing-retinal-hemorrhage-patterns-aids-in-diagnosing-abuse.healio.com; 2021 [cited 2023 May 8].
34. Andersson J, Wikström J, Högberg U, Wester K, Thiblin I. External hydrocephalus as a cause of infant subdural haematoma; epidemiological and radiological investigations of infants suspected of being abused. Pediatr Neurol. 2022 Jan;126:26-34.
35. Bhardwaj G, Jacobs MB, Martin FJ, Moran KT, Prelog K, Donaldson C, et al. Photographic assessment of retinal hemorrhages in infant head injury: the Childhood Hemorrhagic Retinopathy Study. J Am Assoc Pediatr Ophthalmol Strabismus. 2017 Feb;21(1):28-33.e2.
36. Rabbitt AL, Kelly TG, Yan K, Zhang J, Bretl DA, Quijano CV. Characteristics associated with spine injury on magnetic resonance imaging in children evaluated for abusive head trauma. Pediatr Radiol. 2020 Jan;50(1):83–97.
37. Choudhary AK, Ishak R, Zacharia TT, Dias MS. Imaging of spinal injury in abusive head trauma: a retrospective study. Pediatr Radiol. 2014 Sep;44(9):1130–40.
38. Geddes JF, Tasker RC, Hackshaw AK, Nickols CD, Adams GGW, Whitwell HL, et al. Dural haemorrhage in non-traumatic infant deaths: does it explain the bleeding in 'shaken baby syndrome'?: Intradural haemorrhage in infants. Neuropathol Appl Neurobiol. 2003 Feb;29(1):14–22.
39. Davison MA, Button KD, Benzel EC, Weaver BT, Rundell SA. A Biomechanical Assessment of Shaken Baby Syndrome: What About the Spine? World Neurosurg. 2022 Jul;163:e223–9.
40. Zhuge W, Ben-Galim P, Hipp JA, Reitman CA. Efficacy of MRI for Assessment of Spinal Trauma: Correlation With Intraoperative Findings. J Spinal Disord Tech. 2015 May;28(4):147–51.
41. Atkinson N, Van Rijn RR, Starling SP. Childhood Falls With Occipital Impacts: Pediatr Emerg Care. 2018 Dec;34(12):837–41.
42. Hughes J, Maguire S, Jones M, Theobald P, Kemp A. Biomechanical characteristics of head injuries from falls in children younger than 48 months. Arch Dis Child. 2016 Apr;101(4):310–5.
43. Anderst J, Carpenter S, Frazier T, Appavu B, Noetzel M, Beslow LA, et al. Subdural hemorrhage in a cohort with cerebral sinovenous thrombosis: Application to abusive head trauma. Child Abuse Negl. 2021 Jul;117:105119.
44. Adamsbaum C, Laurent-Vannier A. Shaken baby syndrome or non-accidental head injury caused by shaking. Update of the guidelines issued by the 2011 hearing commission. Haute Autorité de santé (HAS) and Société française de médecine physique et de réadaptation (SOFMER); 2017.
45. Goodrich JT. Reprint of 'Concerning Surgical Intervention for the Intracranial Hemorrhages of the New-born' by Harvey Cushing, M.D. Childs Nerv Syst. 2000 Aug 30;16(8):484–92.
46. Zahl SM, Mack JA, Rossant C, Squier W, Wester K. Thrombosis is not a marker of bridging vein rupture in infants with alleged abusive head trauma. Acta Paediatr. 2021 Oct;110(10):2686–94.
47. Wester K, Stridbeck U, Syse A, Wikström J. Re-evaluation of medical findings in alleged shaken baby syndrome and abusive head trauma in Norwegian courts fails to support abuse diagnoses. Acta Paediatr. 2022 Apr;111(4):779-792.
48. Raissaki M, Adamsbaum C, Argyropoulou MI, Choudhary AK, Jeanes A, Mankad K, et al. Benign enlargement of the subarachnoid spaces and subdural collections—when to evaluate for abuse. Pediatr Radiol. 2023 Mar 1;53(4):752–67.
49. Strouse PJ. Child abuse: we have problems. Pediatr Radiol. 2016 May;46(5):587–90.
50. Macdonald S, Squier W, Kirkwood H, Luttner S, Lynøe N, Marshall D, et al. Prometheus Shaken Baby Debate. Researchers.One [Internet]. 2019. [cited 2023 Feb 15]. Available from: https://researchers.one/articles/19.03.00003v1
51. Watkins SJ. The law is not equipped to consider scientific dispute. BMJ. 2016 Mar 31;i1768.

14698749, 0, Downloaded from https://onlinelibrary.wiley.com/doi/10.1111/dmcn.15676 by University College London UCL Library Services, Wiley Online Library on [24/06/2023]. See the Terms and Conditions (https://onlinelibrary.wiley.com/terms-and-conditions) on Wiley Online Library for rules of use; OA articles are governed by the applicable Creative Commons License

52. Kato M, Nonaka M, Akutsu N, Narisawa A, Harada A, Park YS. Correlations of intracranial pathology and cause of head injury with retinal hemorrhage in infants and toddlers: A multicenter, retrospective study by the J-HITs (Japanese Head injury of Infants and Toddlers study) group. PLoS One. 2023 Mar 17;18(3):e0283297. Available from: https://journals.plos.org/plosone/article/peerReview?id=10.1371/journal.pone.0283297
53. Findley K, Rossant C, Sasakura A, et al. Shaken Baby Syndrome: Investigating the Abusive Head Trauma Controversy. Cambridge: Cambridge University Press; 2023.

How to cite this article: Squier W. Retinodural haemorrhage of infancy, abusive head trauma, shaken baby syndrome: The continuing quest for evidence. Dev Med Child Neurol. 2023;00:1–8. https://doi.org/10.1111/dmcn.15676

14698749, 0, Downloaded from https://onlinelibrary.wiley.com/doi/10.1111/dmcn.15676 by University College London UCL Library Services, Wiley Online Library on [24/06/2023]. See the Terms and Conditions (https://onlinelibrary.wiley.com/terms-and-conditions) on Wiley Online Library for rules of use; OA articles are governed by the applicable Creative Commons License